



Success Rate of *Thorax* Ultrasonography in Assisting Thoracocentesis Action in Clinical Pulmonary Tuberculosis at Respira Lung Hospital Yogyakarta

Siham Reifqie Fath^{1*}, Sudiyono Sudiyono², Rini Indrati³, Tri Asih Budiati⁴, Gatot Murti Wibowo⁵

¹⁻⁵Postgraduate Program, Poltekkes Kemenkes Semarang, Indonesia

Author correspondence: vivifathony97@gmail.com*

Abstract. The use of X-ray Thorax (XCR Thorax) in assisting thoracocentesis procedures has some limitations. XCR Thorax only provides a two-dimensional image, which may limit the accuracy in determining the exact location for the puncture. In addition, XCR Thorax cannot detect septation or loculation which may affect the success of the thoracocentesis procedure. Thoracic ultrasonography offers advantages in detecting pleural effusion compared to conventional radiographic methods, but has not been standardized in national guidelines. This study aims to see the difference in the success rate of thoracocentesis between the use of thoracic ultrasound guidance and thoracic photo guidance in patients with clinical tuberculosis at Respira Lung Hospital Yogyakarta. This cross-sectional study used a static group comparison approach to compare the success rate of thoracocentesis between two groups at Respira Lung Hospital Yogyakarta: 30 patients with Thorax ultrasound and Thorax photo guidance (Group A) and 30 patients only with Thorax photo guidance (Group B). With a purposive sampling method and analysis using the chi-square test, this study aims to analyze differences in the success rate of thoracocentesis in real clinical conditions without intervening in existing procedures in the hospital. Thoracocentesis with thorax photo plus thorax ultrasound guidance showed a success rate of 100% compared to 66.67% in procedures with thorax X-ray alone ($p < 0.001$). The results showed that the use of thoracic ultrasound as a thoracocentesis guide had a higher success rate compared to the use of thoracic photo guidance.

Keywords: Tuberculosis, Ultrasound, X-ray, Pleural Effusion, Thoracosynthesis

1. INTRODUCTION

Tuberculosis or TB or the term that is often known to the public, namely tuberculosis, is a chronic infectious disease caused by mycobacterium bacteria. Most bacteria often infect the pulmonary parenchyma and cause lung disease, but these bacteria also have the ability to infect other organs outside the lungs (extra lungs).

The World Health Organization (WHO) released a global report for 2022. It is estimated that 10.6 million people suffered in 2021, up from 10.1 million cases in 2020 and 1.6 million deaths as a result in 2021. The high rate of death and illness because this should not happen considering that this disease can be prevented, by performing early detection, including optimizing the use of ultrasound .

Thorax ultrasound is a very effective way of detecting pleural effusion even in simple entities, so ultrasound works better than *thorax* x-rays. Ultrasound can be used as a guide for some procedures involving the pleura and *thorax* wall. This procedure includes, among others, thoracocentesis. Thoracocentesis itself is an invasive procedure carried out by plunging the pleural cavity. This procedure can be performed for diagnostic purposes (taking a sample of

fluid for examination) or for therapeutic purposes (removing excess fluid from the pleural cavity) .

Services at Respira Lung Hospital Yogyakarta, for thoracocentesis procedures in patients with clinical pulmonary tuberculosis are carried out with two different approaches. Some patients only have a *thorax* photo examination before the procedure, while others have a *thorax* photo examination accompanied by ultrasound (ultrasound) guidance for thoracocentesis. This difference in approach raises questions about the effectiveness of the use of ultrasound in improving the success and safety of thoracocentesis procedures.

This study aims to see the difference in the success rate of thoracocentesis between those who use ultrasound guidance and those that are based only on existing *thorax* photos. Based on this background, the author will conduct research with the theme "The Success Rate of Thorax Ultrasound in Assisting *Thoracocentesis* in Pulmonary Tuberculosis Clinical Treatment at Respira Lung Hospital Yogyakarta".

2. LITERATURE REVIEW

Thorax Ultrasound (Ultrasound)

Thorax ultrasound is a technique that utilizes ultrasound waves to produce images of the thorax cavity, especially the lungs, in the chest and back area. Today, the procedure can be performed directly at the patient's bedside, providing convenience and practicality. Using this method, lung tissue abnormalities can be detected through emerging artifacts, as well as aiding in the implementation of invasive measures.

Pleural effusion

Pleural effusion is the accumulation of fluid inside the chest cavity. This collected fluid is in the form of a clear liquid and can be in the form of exudate or exudate, but it can also be in the form of blood or pus . Pleural effusion occurs due to an imbalance between the production and absorption of fluid in the capillaries and visceral pleura. The goal of treating pleural effusion is to reduce symptoms or provide a dispensation

a. Thoracocentesis

Thoracocentesis is a medical procedure in which a needle is inserted into the pleural cavity (the space between the lungs and the *thorax* wall) to remove fluid. This procedure is usually performed for diagnosis or therapy, especially in the case of pleural effusion (accumulation of fluid in the pleural cavity).

1) Indications for Thorakosentesis

- a) Pleural effusion of unknown cause,
- b) Symptoms that worsen or do not respond to therapy, in patients who have received optimal medical therapy (Optimal Medical Therapy or OMT) but do not show improvement, or if symptoms worsen, diagnostic thoracotomies are recommended. It is important to evaluate whether there is a more serious underlying condition such as infection or malignancy.
- c) Additional symptoms such as fever or pleuritis,
- d) Postoperative evaluation or specific medical conditions,

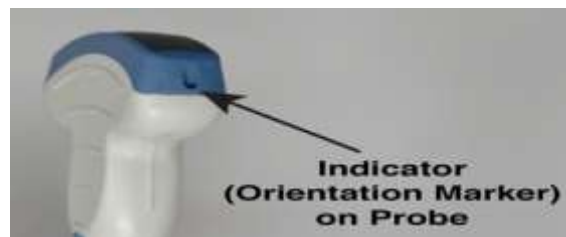2) Benefits of Thorakosentesis

Benefits for determining the cause of effusion, such as infection, malignancy, or other systemic diseases.

3) Thorakosentesis Procedure

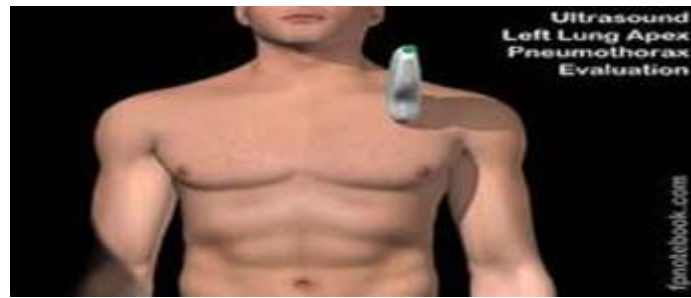Thorakosentesis is carried out with the following steps:

- a) Preparation of the patient, the patient is usually asked to sit with his hands raised or lying on his side.
- b) Local anesthesia, area to be inserted the needle is given local anesthesia.
- c) Insertion of the needle, inserted through the *thorax* wall into the pleural cavity under ultrasound guidance or blindly based on clinical anatomy.

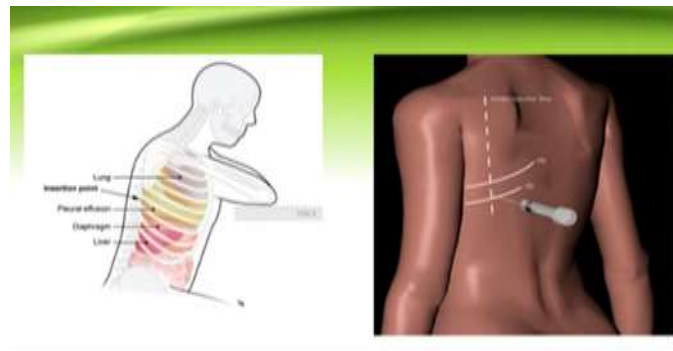


Picture 1. Transducer marking indicator

The structure within the *thorax* cavity can be visualized by maintaining the transducer along the longitudinal axis (sagittal). Anatomical landmarks can help the examination, especially in performing pleural punctures. The right pleural surface is limited by the diaphragm and liver, while the left side is limited by the diaphragm and spleen. The transducer can be placed at multiple locations along the *thorax*, depending on the anomaly of the location being examined.



Picture 2. Patient position and transducer location



Picture 3. Planting location and operation location (marker)

Normal *thorax* ultrasound image, using a low-frequency transducer (3.5 MHz) pwith a normal *thorax* wall, ecogenic image showing a connective tissue layer consisting of muscles and *fascia*. The pleural layers appear to move during inspiration and expiration. With *real-time imaging*, the movement of the pleural layer known as *gliding signs* will be seen. Pulmonary breathing movements against the *thorax* wall called *lung sliding sign* ²³.

Ultrasound can better show the presence of pleural effusion and its number size. In addition, ultrasound can determine whether there are complications of pleural effusion, such as pleural effusion with fibrin and septicsacs ²⁴. Thus this study shows that ultrasound is a fast and accurate way to help determine the presence of clinically significant peura effusion to perform the act of thoracotosentesis ²¹.

b. Tuberculosis

Tuberculosis is an infectious disease caused by *Mycobacterium Tuberculosis* (M.Tb) ². These germs usually attack the lungs (pulmonary TB), but can also attack other organs (extrapulmonary TB)¹. Extra pulmonary tuberculosis (TB) is a bacteriological or clinically diagnosed case of TB involving organs other than the lungs, such as the pleura, lymph nodes, abdomen, genital tract, skin, bones, joints, and brain membranes. Pleural fluid analysis is an important examination in the diagnosis of pleural tuberculosis. The pleural fluid retrieval procedure is performed through thoracocentesis, which serves both for diagnosis and therapy. Thorakosenesis is performed if the volume of fluid collected is sufficient to be aspirated, with a thickness of at least 10 mm on thorax ultrasound examination.

2. METHODS

This study uses a cross-sectional design with a static group comparison approach³¹. This design was chosen to look at the difference in the success rate of the thoracocentesis action at one specific time point, without conducting an experimental intervention. The static group comparison approach allows researchers to compare the results of the two existing groups, without randomization or intervention. This is in accordance with the purpose of the study to see the difference in success rates in clinical practice that is already running.

3. RESULTS

Success Rate of Thorakocentesis Procedure With *Thorax* Guided Ultrasound

General Characteristics of Research Sample

From the results of the research conducted at Respira Lung Hospital, data were obtained from a total of 60 research samples with the following characteristics:

Table 1. Characteristics of the Research Sample		
Characteristic	Frequency	Percentage (%)
Age		
18-30 years	9	15
31-45 years	12	20
46-60- years old	22	36,67
61-75 years	14	23,33
>75 years	3	5
Gender		
Man	45	75
Woman	15	25

From the table of characteristics of the research sample above, the research sample shows an age distribution that tends to lead to an older population. The majority of patients were in the age group of 46-60 years (36.67%), followed by the group of 61-75 years (23.33%). In the interpretation of the results, it is necessary to consider age and gender factors, especially if significant differences are found in the response to the act of thoracocentesis based on these characteristics.

Success Rate Of Thorakosentesis Procedure With *Thorax* Guiding Ultrasound

In this study, the success of the thoracotosentesis action was measured using a systematic and objective approach, focusing on two main criteria: the success status of the procedure and the volume of aspirated fluid. The success status of the procedure is assessed as "Successful" if the needle successfully enters the pleural cavity and the fluid can be aspirated, while the procedure is considered "Failed" if the needle does not successfully enter the pleural cavity or there is no aspirable fluid. The details of the volume of aspirated fluid are not explicitly mentioned in the result data, but are contained in the appendix as a reinforcement of the research results.

The results of this study present a comprehensive analysis of the success rate of thoracocentesis in patients with pleural effusion, by comparing procedures using *Thorax* ultrasound guidance and procedures that rely solely on *thorax* photo interpretation. This analysis aims to provide a clear picture of the use of *Thorax* ultrasound in improving the success of the action.

Table 2. Successful thoracocentesis using CXR and guiding Thorax ultrasound

Sample	Torakosentesis (<i>Thorax</i> ultrasound)
1	Succeed
2	Succeed
3	Succeed
4	Succeed
5	Succeed
6	Succeed
7	Succeed
8	Succeed
9	Succeed
10	Succeed
11	Succeed
12	Succeed
13	Succeed
14	Succeed
15	Succeed
16	Succeed
17	Succeed
18	Succeed
19	Succeed
20	Succeed
21	Succeed
22	Succeed
23	Succeed
24	Succeed
25	Succeed
26	Succeed
27	Succeed
28	Succeed
29	Succeed
30	Succeed

Based on the data from the study, it can be analyzed that the thoracocentesis procedure with *Thorax* ultrasound guidance shows a very high success rate. Of the 30 samples conducted, all (100%) succeeded without any failure. This indicates that the use of *Thorax* ultrasound as a guide in thoracocentesis procedures is reliable.

In order to gain a more comprehensive understanding of the success rate of this technique, it is also important to consider the results of the thoracocentesis procedure performed without the use of ultrasound guidance.

Table 3. Success of thoracotosentesis without guided Thorax ultrasound

Sample	Torakosentesis (<i>X-rays of Thorax</i>)
1	Succeed
2	Succeed
3	Succeed
4	Succeed
5	Succeed
6	Succeed
7	Succeed
8	Succeed
9	Succeed
10	Succeed
11	Succeed
12	Succeed
13	Succeed
14	Succeed
15	Succeed
16	Succeed
17	Succeed
18	Succeed
19	Succeed
20	Succeed
21	Fail
22	Fail
23	Fail
24	Fail
25	Fail
26	Fail
27	Fail
28	Fail
29	Fail
30	Fail

Based on the table regarding the success status and the volume that can be aspirated during the thoracotosentesis procedure without the guidance of *Thorax* ultrasound, it shows informative results. Of the total 30 procedures carried out, 20 cases (66.67%) were successfully implemented, while 10 cases (33.33%) failed. This success rate illustrates that the conventional method without ultrasound guidance still has quite good effectiveness in the implementation of thoracotocentesis.

Statistical Analysis of the Success Rate of Thorakocentesis Procedures Using Thorax Ultrasound Guidance and Without Thorax Ultrasound Guidance

The results of these statistical tests strongly support the alternative hypothesis and suggest that the use of thorax ultrasound as a guide in the act of thoracotosentesis provides significant benefits in improving the success rate of the procedure in patients with clinical tuberculosis compared to relying solely on thorax photographs.

The analysis of the results showed that both the thoracocentesis method guided by Thorax ultrasound and those that only used thorax photos had the same sensitivity, which was 100%. This indicates that both methods are very effective in detecting the presence of pleural effusion in all cases studied. In other words, there are no cases of pleural effusion that these two methods miss.

4. DISCUSSION

Success Rate of Thoracocentesis Procedure With Thorax Guided Ultrasound

The success rate of thoracocentesis procedures with Thorax ultrasound guidance shows very promising results. Based on research data, procedures using Thorax ultrasound guidance achieved a 100% success rate, while procedures without ultrasound guidance were only successful in 66.67% of cases. This significant difference ($p < 0.001$) underscores the important role of ultrasound in improving the success of thoracocentesis procedures.

The advantages of using *Thorax* ultrasound as a guide in the action of thoracocentesis can be explained through several factors. First, ultrasound allows for real-time visualization of the anatomical structure of *the thorax*, allowing for more accurate determination of the location of needle insertion. This is in line with the findings of Diacon et al.³⁴ who reported an increase in needle insertion location accuracy of up to 25% using ultrasound. This higher accuracy contributes directly to a higher success rate of the procedure and reduces the risk of complications.

The ability of ultrasound to provide a dynamic picture during the procedure allows for real-time adjustment of the technique if needed. This can be very beneficial in dealing with anatomical variations or complex pleural conditions, which may not be detected using just thorax X-ray photographs. These advantages show that the use of ultrasound in thoracocentesis not only increases the success rate, but also improves the overall safety and efficiency of the procedure. This finding is corroborated by the research of Salamonsen et al.³⁵, which demonstrated that the use of ultrasound allows for the identification of optimal locations for needle insertion, thereby increasing aspiration volume and reducing the risk of complications.

The results of this study, supported by the current literature, provide strong evidence that the use of *Thorax* ultrasound as a guide in thoracocentesis procedures significantly improves the success rate and safety of the procedure. These findings support the integration of *Thorax* ultrasound as a standard in the implementation of thoracocentesis procedures, especially in complex or high-risk cases. Thus, the use of *Thorax* ultrasound has the potential

to improve the standard of care in the management of pleural effusion and thoracocentesis procedures.

5. CONCLUSION AND SUGGESTIONS

Conclusion

Based on the results of the study, it can be concluded that the use of Thorax ultrasound as a guide in the thoracocentesis procedure significantly increased the success rate of the procedure by 100%, compared to 66.67% without ultrasound, with a statistical test significance level of $p < 0.001$. This technology enables real-time visualization of anatomical structures, improves needle placement accuracy, and aids in the identification of complex conditions such as loculated effusion, thereby improving the success of procedures and reducing the risk of repeatability. These findings support the integration of Thorax ultrasound as a standard in the implementation of thoracocentesis procedures.

Suggestions

- 1) It is recommended to adopt the use of Thorax ultrasound as the primary guiding method in thoracocentesis procedures in healthcare facilities.
- 2) Training: Comprehensive training is needed for medical personnel to improve their skills in the use of Thorax ultrasound for thoracocentesis procedures.
- 3) Further Research: More research is needed to evaluate the long-term impact of Thorax ultrasound use on the economic aspects of health and clinical outcomes of patients.

REFERENCES

- Arikunto. (2020). *Prosedur suatu pengantar pendekatan praktek*. Rineka Cipta.
- Black, J., & Hawks, J. (2019). *Medical Surgical Nursing* (Vol. 2). Salemba Medika.
- Caiulo, V. A. (2014). Point-of-care ultrasonography [4]. *Med e Bambino*, 33(8).
- Cao, W., Wang, Y., Zhou, N., & Xu, B. (2016). Efficacy of ultrasound-guided thoracentesis catheter drainage for pleural effusion. *Oncology Letters*, 12(6). <https://doi.org/10.3892/ol.2016.5244>
- Conlon, T. W., Nishisaki, A., Singh, Y., Bhombal, S., De Luca, D., Kessler, D. O., & et al. (2019). Moving beyond the stethoscope: Diagnostic point-of-care ultrasound in pediatric practice. *Pediatrics*.
- D'Agostino, H., & Edens, M. (2020). *Physiology, Pleural Fluid*.
- Diacon, A. H., Brutsche, M. H., & Solèr, M. (2003). Accuracy of pleural puncture sites: A prospective comparison of clinical examination with ultrasound. *Chest*, 123(2), 436–441. <https://doi.org/10.1378/chest.123.2.436>

- Dietrich, C. F., Mathis, G., Cui, X. W., Ignee, A., Hocke, M., & Hirche, T. O. (2015). Ultrasound of the pleurae and lungs. *Ultrasound in Medicine & Biology*, 41(2), 351–365. <https://doi.org/10.1016/j.ultrasmedbio.2014.10.002>
- Fentress, M., Ugarte-Gil, C., Cervantes, M., et al. (2020). Lung ultrasound findings compared with chest X-ray findings in known pulmonary tuberculosis patients: A cross-sectional study in Lima, Peru. *The American Journal of Tropical Medicine and Hygiene*, 103(5). <https://doi.org/10.4269/ajtmh.20-0542>
- Fitriani. (2020). *Buku ajar TB paru, ASKEP, dan pengawasan minum obat dengan media telepon*.
- Fong, C., Tan, C. W. C., Tan, D. K. Y., & See, K. C. (2021). Safety of thoracentesis and tube thoracostomy in patients with uncorrected coagulopathy: A systematic review and meta-analysis. *Chest*, 160(5), 1875–1889. <https://doi.org/10.1016/j.chest.2021.04.036>
- Gordon, C. E., Feller-Kopman, D., Balk, E. M., & Smetana, G. W. (2010). Pneumothorax following thoracentesis: A systematic review and meta-analysis. *Archives of Internal Medicine*, 170(4), 332–339. <https://doi.org/10.1001/archinternmed.2009.548>
- Hulmansyah, D., Santoso, B., & Budiarti, T. A. (2023). Implementation of MRI (magnetic resonance imaging) information system to improve service quality in radiology room Arifin Achmad General Hospital. *International Journal of Radiology & Diagnostic Imaging*, 6(3), 87–92.
- Kementerian Kesehatan Republik Indonesia. (2013). *Pedoman nasional pelayanan kedokteran tentang tatalaksana TBC*.
- Kementerian Kesehatan Republik Indonesia. (2014). *Profil kesehatan Indonesia tahun 2014*. Kemenkes RI.
- Kementerian Kesehatan Republik Indonesia. (2020). *Pedoman nasional tata laksana tuberkulosis (TBC)*.
- Kementerian Kesehatan Republik Indonesia. (2021). *Peraturan Presiden Nomor 67 tahun 2021 tentang penanggulangan tuberkulosis*. Kementerian Kesehatan RI.
- KNCV Indonesia. (2022). *Laporan kasus tuberkulosis (TBC) global dan Indonesia 2022*. <https://yki4tbc.org/laporan-kasus-tbc-global-dan-indonesia-2022/#:~:text=Insidensi%20kasus%20TBC%20di%20Indonesia,di%20antaranya%20yang%20menderita%20TBC>.
- Koenig, S. J., Narasimhan, M., & Mayo, P. H. (2011). Thoracic ultrasonography for the pulmonary specialist. *Chest*, 140(5), 1332–1341. <https://doi.org/10.1378/chest.11-0348>
- Mercaldi, C. J., & Lanes, S. F. (2013). Ultrasound guidance decreases complications and improves the cost of care among patients undergoing thoracentesis and paracentesis. *Chest*, 143(2), 532–538. <https://doi.org/10.1378/chest.12-0447>

- Mohamed, E. S. M. (2018). In diagnosis of pleural effusion and pneumothorax in the intensive care unit patients: Can chest ultrasound replace bedside plain radiography? *The Egyptian Journal of Radiology and Nuclear Medicine*, 49(2), 346–351. <https://doi.org/10.1016/j.ejnm.2018.02.006>
- Mustaqin. (2018). *Asuhan keperawatan gangguan sistem perkemihan*. Salemba Medika.
- Na, M. J. (2014). Diagnostic tools of pleural effusion. *Tuberculosis and Respiratory Diseases*, 76(5). <https://doi.org/10.4046/trd.2014.76.5.199>
- Poni, N. J., Arntfield, R., & KP. (2020). *Point of care ultrasound* (2nd ed.). Elvisier.
- Pranita. (2018). Diagnosis dan tatalaksana terbaru penyakit pleura. *Wellness Journal Press*, 10. Available at: <https://wellness.journalpress.id/wellness/article/download/21010/pdf>
- Rea, G., Sperandeo, M., Lieto, R., et al. (2021). Chest imaging in the diagnosis and management of pulmonary tuberculosis: The complementary role of thoracic ultrasound. *Frontiers in Medicine*, 8(December), 1–9. <https://doi.org/10.3389/fmed.2021.753821>
- Saferi. (2017). *Keperawatan medikal bedah keperawatan dewasa*. Nuha Medika.
- Salah, A. I., El-Serwi, H. B., Ansary, A. M., & Houssien, A. B. I. (2021). Pleural ultrasonography versus chest radiography for the diagnosis of pneumothorax. *QJM: An International Journal of Medicine*, 114(Supplement_1). <https://doi.org/10.1093/qjmed/hcab086.004>
- Sikora, K., Perera, P., Mailhot, T., & Mandavia, D. (2012). Ultrasound for the detection of pleural effusions and guidance of the thoracentesis procedure. *ISRN Emergency Medicine*, 2012, 1–10. <https://doi.org/10.5402/2012/676524>
- Soni, N. J., Franco, R., Velez, M. I., et al. (2015). Ultrasound in the diagnosis and management of pleural effusions. *Journal of Hospital Medicine*, 10(12), 811–816. <https://doi.org/10.1002/jhm.2434>
- Sugiyono. (2020). *Statistika penelitian*. Raja Grafindo.
- Taylor, A., & Anjum, F. (2021). Thoracic and lung ultrasound. In *StatPearls Publishing*. <https://www.ncbi.nlm.nih.gov/books/NBK500013>
- Williamson, J. P., Grainge, C., Parameswaran, A., & TSH. (2017). Thoracic ultrasound: What non-radiologists need to know. *Current*, 6(1), 39–47. <https://doi.org/10.1007/s13665-017-0164-1>
- Winaya, E., & Koesoemoprodjo, W. (2015). Peranan ultrasonografi thorax dalam menegakkan diagnosis beberapa kelainan pada paru (Vol. 1).