

Case Report of Phacolytic Glaucoma in the Eye Department of Dr. M. Djamil Hospital Padang

Fitria Rahmi Nukti^{1*}, Fitratul Ilahi²

¹Medical Doctor Profession Program, Faculty of Medicine, Andalas University, Padang City

²Department of Ophthalmology, Faculty of Medicine, Andalas University, Padang City

Email: frnukti@gmail.com¹, fitratulilahi54@yahoo.com²

Corresponding author: frnukti@gmail.com*

Abstract. A 68-year-old man came to the polyclinic at a type A hospital in West Sumatra with complaints of pain in the right eye since 3 weeks before coming to the hospital. Anamnesis and physical examination were performed on the patient and a diagnosis of phacolytic glaucoma was established. This article aims to report a case of phacolytic glaucoma which is a rare case of secondary open-angle glaucoma.

Keywords: Phacolytic Glaucoma, Secondary Open-angle Glaucoma, Cataracts

1. INTRODUCTION

Glaucoma is a complex eye condition characterized by elevated intraocular pressure (IOP) that can progress to vision loss over time. Glaucoma is the second leading cause of permanent blindness in the United States and is most common in older adults (Ezinne et al, 2022). Glaucoma can be categorized into primary or secondary types and further into open-angle or closed-angle variants within each glaucoma type. Adult glaucoma includes primary open-angle glaucoma (POAG) and angle-closure glaucoma, as well as secondary open-angle and angle-closure glaucoma (Mahabadi et al, 2024). with a special focus on the most common type, POAG.

Lens-induced glaucoma (LIG) is a secondary glaucoma in which the lens plays an important pathogenic role, either due to an increase in its thickness, a change in its position, or due to an inflammatory process (Maiya, 2017). Phacomorphic glaucoma accounts for the majority of LIG cases followed by phacolytic glaucoma (Macovei, 2021). Phacolytic glaucoma, a rare secondary open-angle glaucoma, is caused by leakage of high molecular weight proteins through the hypermature cataract capsule (Macovei, 2021). Clinical presentation is usually a painful eye, decreased vision and hyperemic conjunctiva.

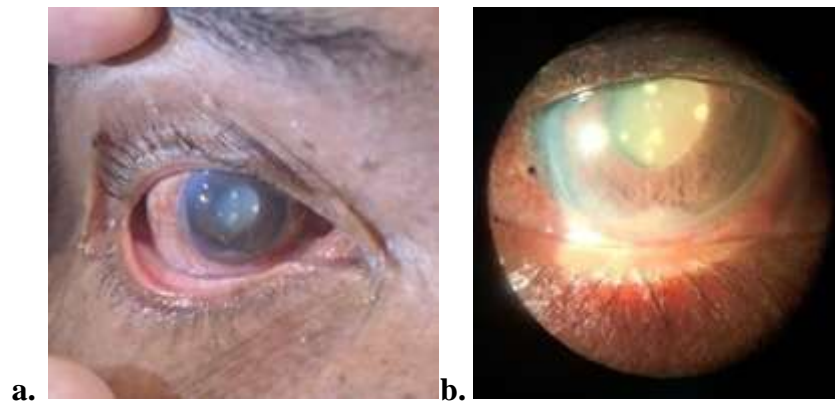
2. CASE REPORT

A 68-year-old man came to the polyclinic at a type A hospital in West Sumatra with complaints of right eye pain since 3 weeks ago which was felt continuously. Apart from the main complaint, the patient also complained of red, itchy and watery eyes and sensitivity to light since 3 weeks ago. Complaints of decreased vision since 3 years ago slowly also felt by

the patient.

There was no history of disease such as malignancy, hypertension, diabetes mellitus or cholesterol in the patient and the patient's family. The general physical examination was normal.

The ophthalmic status examination of the right eye revealed a visus of 1/~, ciliary injection and conjunctival injection in the bulbous conjunctiva. The anterior ocular camera (COA) examination found a deep COA with a mass found and the funduscopy results obtained cloudy media with other funduscopy examination results difficult to assess. In addition, an IOP examination was also performed which resulted in a pressure of 50 mmHg.



Clinical Photograph of the Patient's Right Eye
a. Initial Inspection, b. Slit-Lamp Examination

Based on the results of the history, physical examination and supporting examinations that have been carried out on the patient, a diagnosis of phacolytic glaucoma oculi dextra was made.

This patient was treated with glaucon tab 4x250 mg, aspar K tab 1x300 mg, glaopen ed 1x1 OD, polydex ed 6x1 OD, cendolyteers ed 4x1 OS and trabeculectomy, phacoemulsification and IOL insertion.

3. DISCUSSION

Glaucoma is a condition characterized by gradual loss of peripheral vision and irreversible damage to the optic nerve and retinal ganglion cells, making it a significant public health problem. Its etiology is multifactorial such as anatomical, genetic, vascular and immune factors. Glaucoma is a fundamental public health problem and is the second cause of irreversible blindness after cataract. Currently, glaucoma affects more than 60 million people worldwide, and this number is expected to surpass 110 million by 2040.6 POAG is the most common type, affecting about 2% to 4% of people aged 40 years and above and about 10% of people aged 75 years and above (Dietze, 2024).

Lens-induced glaucoma is not uncommon in low to middle income countries where receipt of healthcare may not only be delayed but access may be poor, or may be unaffordable.⁸ Such glaucoma usually occurs when the cataract becomes mature or hypermature. When a cataract becomes hydrated and swollen, it can lead to angle-closure glaucoma (called phacomorphic) (Pathak, 2021). A hypermature cataract, where the cortex liquefies and lens proteins leak out through the capsule, usually results in open-angle glaucoma (called phacolytic). Morgagni cataracts are extreme hypermature lenses, where the cortex melts away completely and the nucleus sinks to the bottom. Such lenses are more likely to cause phacolytic glaucoma (Eadie, 2019).

Morgagni's cataract occurs in a hypermature state, where the cortex melts completely and is associated with phacolytic glaucoma. Once the cataract is associated with glaucoma, pain appears due to high intraocular pressure. Pain in the eye prompts these patients to consult an ophthalmologist, albeit in a delayed manner (3 weeks after onset). In late onset, trabeculectomy is mandatory in the surgical plan to reduce pain (Pathak, 2021).

In Phacolytic Glaucoma, Epstein described the role of high molecular weight lens protein (HMW- LP) in the pathogenesis of PLG. Microdefects in the cataractous lens capsule lead to progressive leakage of soluble lens proteins into the aqueatic humor. Macrophages phagocytose these proteins and block the trabecular meshwork (TM), leading to acute open-angle glaucoma. Recent theories suggest that HMW-LP directly clogs the TM to inhibit aqueous outflow and trigger PLG. An increase in HMW-LP content in the human lens with age supports this theory (Dietze, 2024). On history taking, common eye complaints in LIG patients are sudden onset of redness, sudden onset of unilateral eye pain, may be accompanied by headache, nausea, and vomiting, gradual progressive deterioration of vision in cataract cases as well as colored halos, photophobia, and epiphora.

Clinical examinations that can be performed include examination of the ocular adnexa with possible swelling and redness of the eyelids, conjunctival congestion and chemosis, dilated episclera vessels, increased IOP causing stromal edema, subepithelial bullae, and Descemet's membrane folds. PAG and PLG cases show precipitating keratitis on the posterior surface of the cornea. Lens proteins precipitated on the posterior surface of the cornea, the aqueatic humor in the front eye chamber showed lens particles. PLG shows hyper-refrangent particles consisting of calcium oxalate or cholesterol crystals (Dietze, 2024).

Lens examination reveals an intumescent mature senile cataract (MSC). On LPIG, lens capsule rupture with lens cataract may be seen. PLG may show MSC or HMSC. The primary goal of treatment in LPIG is adequate IOP control with the definitive treatment being removal

of the triggering lenticular material. IOP management in LAG is topical antiglaucoma medications with first-line management including beta-blockers, alpha-agonists, and carbonic anhydrase inhibitors. Prostaglandin analogs and miotics can be used but may increase intraocular inflammation. Systemic IOP-lowering agents with hyperosmotic agents (e.g., mannitol) and carbonic anhydrase inhibitors (acetazolamide) can further enhance the effect of topical agents. Close monitoring of renal function and serum electrolytes is essential.

Topical and systemic corticosteroids can also be given to reduce inflammation in the PLG before definitive cataract surgery and lens extraction is performed after adequate IOP control with conventional ECCE techniques, small incision cataract surgery (SICS), or phacoemulsification is used to remove the lens. In cases of PLG, immediate lens extraction alone results in well-controlled IOP if the previous history is less than a week. For a history of more than 2 weeks, combined cataract surgery with trabeculectomy showed better IOP control (Dietze, 2024). This patient was given management in the form of giving glaucon tab which is the first line of beta-blocker drugs, aspar K tab which is used as a prophylaxis for the use of acetazolamide, glaopen and polydex ed which is a class of prostaglandin analogs, and cendolyteers ed which is artificial tears to keep the eyes dry and also performed trabeculectomy, phacoemulsification and IOL installation to treat glaucoma and cataract removal in this patient.

4. SUMMARY

Glaucoma is not a benign disorder, and if left untreated, can lead to permanent vision loss. The higher the pressure and duration of elevated IOP, the greater the risk of optic nerve damage. Timely diagnosis plays an important role in reducing the damage of glaucoma, and early intervention is crucial in preventing and slowing the progression of vision loss. Effective treatment, especially in maintaining low IOP levels, can often produce positive results, preserve visual field integrity and halt disease progression.⁷

5. ACKNOWLEDGEMENT

The researchers would like to thank all those who helped in completing and improving this research.

REFERENCES

- Allison, K., Patel, D., & Alabi, O. (2020). Epidemiology of glaucoma: The past, present, and predictions for the future. *Cureus*, 12(11).
- Dhingra, D., Grover, S., Kapatia, G., et al. (2020). Phacolytic glaucoma: A nearly forgotten entity. *European Journal of Ophthalmology*, 30(5), 32-35.
- Dietze, J., Blair, K., Zeppieri, M., & Havens, S. J. (2024). *Glaucoma*. StatPearls Publishing.
- Eadie, B., Heathcote, J., & Gupta, R. (2019). Acute phacolytic glaucoma and morgagnian cataract. *JAMA Ophthalmology*, 137.
- Ezinne, N., Shittu, O., Ekemiri, K., et al. (2022). Visual impairment and blindness among patients at Nigeria Army Eye Center, Bonny Cantonment, Lagos, Nigeria. *Healthcare*, 10(11).
- Gonzalez-Arocha, C. S., Gonzalez-Cortes, J. H., & Treviño-Herrera, A. B. (2023). Phacolytic glaucoma at a glance. *Latin American Journal of Ophthalmology*, 6, 5.
- Han, R. J., Tian, A. J., Wu, Y. X., et al. (2023). A case report of phacolytic glaucoma in lens cortex behind posterior capsule: A care-compliant article. *Medicine*, 102(44).
- Jiang, Z., Wei, Y., & Yang, Y. (2023). A late-onset phacolytic glaucoma. *Ophthalmology Glaucoma*, 6(6).
- Macovei, M. L., Madalina, C., & Neagoe, B. M. (2021). Phacolytic glaucoma. *Romanian Journal of Ophthalmology*, 65(2), 191-195.
- Mahabadi, N., Zeppieri, M., & Tripathy, K. (2024). *Open angle glaucoma*. StatPearls Publishing.
- Maiya, A. (2017). Lens-induced glaucoma in the rural population: Is cataract surgery in one eye a boon or bane? *Indian Journal of Clinical and Experimental Ophthalmology*, 3(1), 24-27.
- Nannaware, S. L., Singasandra, S. M., Mallaiah, D., et al. (2021). *International Journal of Ocular Oncology and Oculoplasty*, 7(4), 372-377.
- Pathak-Ray, V. (2021). Morgagnian cataract and phacomorphic glaucoma. *Indian Journal of Ophthalmology*, 1(1), 50-51.
- Sardar, K., Avik, K. R., & Aparna, R. (2022). A comparison of clinical profile and treatment outcomes of phacomorphic and phacolytic glaucoma in a tertiary eye care hospital of India. *Nigerian Journal of Ophthalmology*, 30(2), 51-55.
- Wagner, I., Stewart, M., & Dorairaj, S. (2022). Updates on the diagnosis and management of glaucoma. *Mayo Clinic Proceedings: Innovations, Quality & Outcomes*, 6(6), 618-635.