

Case Report: Conjunctivitis in Children

by Kaherma Sari

Submission date: 30-Aug-2024 12:13PM (UTC+0700)

Submission ID: 2441012713

File name: AHERMA_-_Konjungtivitis_Jurnal_CMJ_Thalia_Shalsabillah-1_1.docx (285.16K)

Word count: 2110

Character count: 12480

Case Report: Conjunctivitis in Children

Kaherma Sari^{1*}, Thalia Shalsabillah²

¹ Tengku Rafian Regional Hospital, Siak, Indonesia

² Doctoral Profession Study Program, Faculty of Medicine, Abdurrahman University, Indonesia

Jl. Riau Ujung No. 73 Pekanbaru – Riau – Indonesia

Correspondent: kahermasari@univrab.ac.id *

Abstract. Conjunctivitis is an inflammation of the conjunctiva, the mucous membrane covering the back of the eyelids and the eyeball, which can be acute or chronic. This condition is characterized by conjunctival hyperemia, edema, and discharge. Causes of conjunctivitis include bacteria, chlamydia, allergies, viruses, and systemic diseases. The incidence of conjunctivitis varies by age, sex, and season. Although slightly more common in women in emergency departments, the seasonal pattern of conjunctivitis is consistent across regions. Allergic conjunctivitis, which affects 15-40% of the population, is most common in the spring and summer. Bacterial conjunctivitis is most common from December to April. Acute bacterial conjunctivitis is generally self-limited, with symptoms lasting 1-3 days if treated appropriately, but can last 10-14 days if left untreated. Staphylococcal and gonococcal conjunctivitis can lead to chronic complications or serious problems such as corneal perforation. Viral conjunctivitis usually gets worse in 4-5 days and resolves in 1-2 weeks. Complications are rare but can include corneal problems and life-threatening conditions such as meningitis or sepsis.

Keywords: Conjunctivitis, Bacteria, Red Eye

1. INTRODUCTION

Conjunctivitis is an inflammation of the conjunctiva or inflammation of the mucous membrane that covers the back of the eyelids and eyeball, in acute or chronic forms, characterized by conjunctival blood vessels which then cause conjunctival hyperemia and edema, which is usually associated with the discharge of secretions. (American Academy of Ophthalmology, 2024).Causes of conjunctivitis include bacteria, chlamydia, allergies, viral toxins, and those associated with systemic diseases. (Ilyas S, Yulianti SR. 2018)

The occurrence of conjunctivitis depends on factors such as age, gender, and time of year. Although the overall rate of conjunctivitis diagnosed in the emergency department is slightly higher in women than in men, the season also plays a role in the presentation and diagnosis of conjunctivitis. Despite changes in climate or weather patterns, seasonal patterns remain consistent across geographic regions, as described in a national emergency department study. Allergic conjunctivitis is the most common cause of conjunctivitis, affecting 15% to 40% of the population, and occurs most frequently in the spring and summer. Rates of bacterial conjunctivitis are highest from December to April. Allergic conjunctivitis is considered the most common allergic eye disease, affecting 15% to 20% to 40% of the population, with both seasonal and perennial types.(Hashmi MF, Gurnani B, Benson S. 2024).

Conjunctivitis is a treatable eye disease and is generally benign. The duration of

symptoms varies depending on the type of conjunctivitis experienced. Acute bacterial conjunctivitis is almost always *self-limited*. If not managed properly it can last up to 10-14 days, and lasts 1-3 days if managed. Exceptions are staphylococcal conjunctivitis (which can progress to blepharoconjunctivitis and become chronic) and gonococcal conjunctivitis (which if not treated, can lead to corneal perforation and endophthalmitis). Chronic bacterial conjunctivitis is usually not *self-limited* and can be difficult to manage. Viral conjunctivitis usually worsens in 4 to 5 days before resolving 1 to 2 weeks later. Death in cases of bacterial conjunctivitis is due to failure to recognize and treat the underlying disease. Meningitis and sepsis caused by *Neisseria gonorrhoeae* can be life-threatening. Complications of acute conjunctivitis are rare. Patients with Herpes Simplex Virus conjunctivitis develop corneal complications and uveitis. Patients with *Neisseria gonorrhoeae* are at risk for corneal involvement and secondary corneal perforation. (Asbury T, Ausburger JJ. 2018).Staphylococcal conjunctivitis often occurs in association with chronic marginal blepharitis. Conjunctivitis with a clinical picture of pseudomembranes and membranes can cause conjunctival scarring, as well as corneal ulceration.(Hashmi MF, Gurnani B, Benson S. 2024).

2. LITERATURE REVIEW

Case Illustration

A 10-year-old male patient came to Tengku Rafi'an Siak Regional Hospital with complaints of red left eye since 2 weeks ago, accompanied by watery and sticky yellow discharge in the morning. The patient's eyes started to turn red since contact with dust while playing soccer. The patient did not complain of blurred vision, pain, or glare. The patient did not have a fever, cough, runny nose, and there were no abnormalities in defecation or urination. The patient has never experienced anything like this. 1 day before treatment, the patient was given Naphazoline from the pharmacy. None of the patient's family members experienced the same thing. The patient often plays outside, especially playing football, and has never experienced anything like this even though he often plays football. Neither the patient nor the patient's family are aware of any history of allergies in the patient.

Based on the ophthalmological examination of the patient, the patient's vision decreased, especially in the affected eye. No abnormalities were found related to the structure of the eyelid, changes in scleral color, lens abnormalities. In addition, left eye conjunctival injection was found, no cobblestone appearance, trantas dot, yellowish mucopurulent discharge, no ciliary injection and corneal infiltrate. Intraocular Pressure Examination,

Fundoscopy and Tonometry were not performed on this patient.

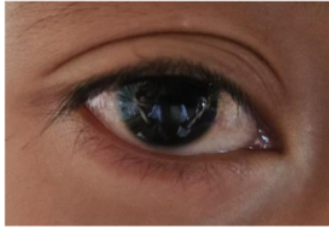


Figure 1 Right eye, no abnormalities were found that were consistent with the patient's complaints.

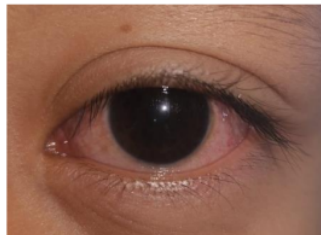

Figure 2 Left eye, conjunctival injection was found without other structural abnormalities of the eye.

Temporary management of patients in this case can be given Levofloxacin 0.5% antibiotic as a broad-spectrum antibiotic prophylaxis therapy due to bacteria that is in accordance with the consideration that microbiological examination has not been carried out as well as supportive therapy such as Sodium Cl + Potassium Cl 0.6 mL for patient's eye complaints.

3. DISCUSSION

A 10-year-old male patient came with a complaint of red eye on the left side since 2 weeks ago. Based on the main complaint, the differential diagnosis can be estimated as widespread conjunctivitis or keratitis. The complaint of red eye is not accompanied by blurred vision, glare when exposed to light so that the diagnosis of keratitis can be ruled out. The patient's complaint of red eye is accompanied by discharge accompanied by watery eyes, not accompanied by itching. The patient was previously exposed to dust when playing ball, so there is suspicion of infectious conjunctivitis. Previously, the patient had no history of similar complaints, the patient had no known history of allergies/atopy, so the etiology of allergies can still be considered. The same complaint was not found in the patient's family, there is no known history of allergies in the family. Based on the anamnesis, several diagnoses can be considered, namely bacterial conjunctivitis because the patient complained of watery eyes and discharge in

the morning, viral conjunctivitis because the patient complained of watery eyes and vernal conjunctivitis because the patient's age is in the risk age range.(Ramadirta N, et al, 2023).

Based on the ophthalmological examination of the patient, left eye conjunctival injection was found, no *cobblestone appearance* , *trantas dot* , yellowish mucopurulent discharge, no ciliary injection and corneal infiltrate. Decreased vision needs to be an additional concern because it could be caused by the cause of the patient's current diagnosis or other etiologies that are not detected or directly related to the current diagnosis.

Based on the findings of anamnesis and ophthalmological examination, where the patient complained of red eyes not accompanied by blurred vision, and no photophobia was found, supported by the findings of ophthalmological examination which showed decreased vision from normal and abnormalities in the conjunctiva but no specific results were found to indicate the etiology of the patient's disease, and no specific supporting examinations were performed, so that the closest diagnosis that can be established in the patient is Conjunctivitis ec Bacteria Oculi Sinistra with Suspected Refractive Disorders.

A definitive diagnosis for this patient can only be made based on supporting ophthalmological examinations, especially bacterial or other microorganism cultures. In this case, it is also important to consider the possibility of mixed infections or superinfections that can affect the clinical pattern of conjunctivitis. This shows the importance of a comprehensive diagnostic approach and not only relying on one method or only limited to clinical symptoms.

Considering the clinical diagnostic approach to this patient, bacterial conjunctivitis is often characterized by a yellow, mucopurulent discharge that accumulates in the corner of the eye, usually seen most often in the morning. In contrast, viral conjunctivitis tends to cause watery eyes with *mucous discharge* and may be accompanied by systemic symptoms such as fever or upper respiratory tract symptoms. Vernal conjunctivitis is more common in children and adolescents, especially in warm climates, and is characterized by serous (watery) discharge and giant papillae on the palpebral conjunctiva, which were not present on physical examination in this patient. Keratoconjunctivitis sicca is characterized by excessive thick mucous discharge and difficulty moving the eyelids, which were also not present in this patient either subjectively or on clinical examination. Fungal conjunctivitis caused by chlamydia also presents with a greenish discharge, which was not present in this patient. The patient's reported exposure to dust while playing football may increase the risk of infection due to minor mechanical trauma to the ocular surface, which may then allow bacterial colonization , strengthening the provisional diagnosis of Bacterial Conjunctivitis. However, given the patient's age and the absence of a history of allergies or similar infections, the possibility of

allergic conjunctivitis should also be considered, although less likely.

Supporting examinations that can be performed on patients include specific microorganism culture examinations, to determine whether the cause of conjunctivitis in patients is due to bacteria or other etiologies. *Skin test examinations* can also be submitted to determine whether the etiology of conjunctivitis is related to possible allergies that have not been previously known by the patient.

Management of conjunctivitis should be based on the cause or etiology, but supporting examinations are needed first, as previously proposed. The patient in this case did not have specific findings for a particular etiology, so temporary management of the patient in this case can be given Levofloxacin 0.5% antibiotic as a broad-spectrum antibiotic prophylaxis therapy due to bacteria that is in accordance with the consideration that microbiological examination has not been carried out and supportive therapy such as Sodium Cl + Potassium Cl 0.6 mL for the patient's eye complaints. Vision correction is not performed until the red eye complaint is resolved because it is a contraindication for the *pinhole test* in vision examination.

The next follow-up recommendation needed by this patient is related to the healing of the red eye complaint, as well as a re-evaluation of the visual impairment of both eyes of the patient with a significant diopter difference, which can raise the possibility of refractive disorders, which need to be considered especially considering the patient's young age so that deterioration at an older age affects the patient's quality of life in the future.

4. CONCLUSION

Conjunctivitis is an inflammation of the conjunctiva, the mucous membrane covering the eyelids and eyeball, and can be acute or chronic. Symptoms include hyperemia, edema, and discharge, with causes such as bacteria, chlamydia, allergies, viruses, and systemic diseases. The incidence of conjunctivitis is influenced by age, gender, and season. Management is adjusted to the etiology of conjunctivitis and is supportive of patient complaints.

This case highlights the importance of a comprehensive diagnostic approach in assessing cases of conjunctivitis in children. Although clinical symptoms can lead to an initial diagnosis, additional investigations are also needed to confirm the etiology and ensure appropriate therapy. The management of this case also emphasizes the importance of proper follow-up to evaluate the effectiveness of therapy and detect complications or other comorbid conditions for a better quality of life of the patient.

BIBLIOGRAPHY

- American Academy of Ophthalmology. (2024). *Conjunctivitis*. EyeWiki.
- American Academy of Pediatrics. (2018). Conjunctivitis in children: Diagnosis and management. *Pediatrics*. Retrieved August 30, 2024, from <https://pediatrics.aappublications.org/content/early/2018/12/10/peds.2018-3211>
- Asbury, T., & Ausburger, J. J. (2011). *Vaughan & Asbury's general ophthalmology* (Riordan-Eva, P., & Cunningham, E. T., Eds.). McGraw-Hill.
- Chan, D. L. W., Smith, J. A., & Brown, K. M. (2020). Conjunctivitis in children: Diagnosis and treatment. *Pediatrics*, 145(1), e20191337. <https://doi.org/10.1542/peds.2020-0137>
- Gilbert, R. S., McLaughlin, J. S., & Rogers, D. M. (2018). Management of conjunctivitis in pediatrics. *Journal of Pediatric Infectious Diseases Society*, 7(4), 340-346. <https://doi.org/10.1093/jpids/piy034>
- Hashmi, M. F., Gurnani, B., & Benson, S. (2024, January). *Conjunctivitis*. StatPearls.
- Ilyas, S., & Yulianti, S. R. (2018). *Ilmu penyakit mata*. Fakultas Kedokteran Republik Indonesia.
- McCormick, J. G. R., & Stager, L. G. Jr. (2016). *Pediatric eye disease*. Springer.
- Ramadirta, N., Maharani, M. P., Agustin, R., Zefanya, I., Rahimah, Y., & Himayani, R. (2023, May). *Konjungtivitis alergi*. Lampung.
- Wright, K. W. (2013). *Pediatric ophthalmology and strabismus*. Elsevier.
- Zemba, K. A., Patel, N. A., & Lee, S. H. (2019). Acute conjunctivitis in children: A review. *Clinical Pediatrics*, 58(5), 565-572. <https://doi.org/10.1177/0009922818822444>

Case Report: Conjunctivitis in Children

ORIGINALITY REPORT

16%

SIMILARITY INDEX

13%

INTERNET SOURCES

3%

PUBLICATIONS

6%

STUDENT PAPERS

PRIMARY SOURCES

1	www.statpearls.com Internet Source	8%
2	garuda.kemdikbud.go.id Internet Source	2%
3	Submitted to Aspen University Student Paper	1%
4	Submitted to Georgia Perimeter College Student Paper	1%
5	Submitted to 2U St. John Fisher College (SJF-MSN) Student Paper	1%
6	"NOMINATIONS AND ELECTIONS", Medical Journal of Australia, 1936 Publication	1%
7	Chidananda Ramappa Devasamudra, Chidananda R Devasamudra. "Intermediate Osteotomy and other Unique Techniques used in Reduction Rhinoplasty", An International Journal Clinical Rhinology, 2016 Publication	1%

8

Submitted to Institute of Technology, Sligo

Student Paper

1 %

9

Ana Zakiyah, Chaterina Janes Pratiwi, Tiwuk Styowati. "Nursing Diagnosis in Perioperative Cataract and Comorbidity", Jurnal Ners dan Kebidanan (Journal of Ners and Midwifery), 2023

Publication

<1 %

10

Rabia Karani. "Chapter 757 Carpenter Syndrome", Springer Science and Business Media LLC, 2018

Publication

<1 %

11

scholars.uthscsa.edu

Internet Source

<1 %

12

doi.org

Internet Source

<1 %

Exclude quotes Off

Exclude matches Off

Exclude bibliography Off